

V. Faria
M. Reis
D. Trigueiros

Departments of Pathology and Urology,
University of Oporto School of Medicine,
Oporto, Portugal

Renal Adenoma: Identification of Two Histologic Types

Key Words

Renal adenoma
Tumor grade
Diagnostic factors

Abstract

In this paper the morphologic characteristics of renal adenoma are studied in 4 groups of kidneys from 500 unselected autopsies performed for legal reasons, 5,000 autopsies from the files of a general hospital, 16 kidneys with adenoma and without carcinoma, and 200 kidneys with carcinoma. All the tumors were classified by pattern, cytology and sclerosis of the renal nontumoral stroma. The relationship between tumor size, tumor histological type and sclerosis was evaluated by statistical analysis. The differences in frequency were significant between the parameters size and histological type ($p < 0.003$), namely for solitary adenomas ($p < 0.001$). The differences in histological type observed in multiple adenomas were not significant ($p > 0.05$). The differences were significant between the extent of sclerosis and histological type ($p < 0.002$) and tumor size ($p < 0.009$). This study identifies two distinct groups of adenomas according to size, histological type and extent of sclerosis, and suggests that small adenomas of the mixed tubulopapillary type and with basophilic cells have little or no malignant potential. Conversely, adenomas with a solid or papillary pattern and clear cells are potentially malignant.

Introduction

The pathogenesis and biological behavior of renal adenoma is controversial. Its relationship with renal carcinoma is uncertain and the distinction between adenoma and carcinoma by morphologic criteria [1-8] is an important challenge in renal tumor diagnosis and prognosis. Tumor size is the most common feature used to distinguish these two entities [1], but it is not a satisfactory criterion: some tumors of <3 cm in diameter exhibit malignant behavior with metastases [1, 3, 5, 9]. Because of the uncertainty in distinguishing adenoma from carcinoma some authors deny the existence of benign renal adenoma and consider this a small cancer [2, 4].

In this paper the morphological characteristics of renal adenoma and its pathogenic relationships with other renal lesions such as sclerosis [10] and renal carcinoma are studied.

Material and Methods

Epithelial tumors found in 68 kidneys belonging to 66 cases were selected by the criteria proposed by Bell [1]: 3 cm or less in size. The tumors were collected from four distinct groups of kidneys.

Group 1 consisted of 597 kidneys obtained from 500 unselected necropsies performed for legal reasons at the Oporto Institute of Forensic Medicine. The kidneys were sectioned serially at approximately 0.2 cm, lengthwise.

Group 2 consisted of kidneys studied retrospectively in 5,000 unselected necropsies from the files of the Hospital of S. João, Porto.

Group 3 consisted of 16 kidneys with small (<3 cm in diameter) solid epithelial tumors (adenomas) without carcinoma, obtained by nephrectomy from patients with pyelonephritis.

Group 4 consisted of 200 kidneys obtained by nephrectomy for renal carcinoma from patients of the Department of Urology of the Hospital of S. João.

Pathological Study

The tumors were classified by histological and cytological type, and arbitrarily by greatest tumor diameter (<0.5 and ≥0.5 cm). In the cases with multiple adenomas we considered only the larger for size classification. Associated renal stromal sclerosis was classified according to the extent as diffuse, localized (peritumoral), mixed or absent, and graded as moderate or severe.

Statistical Analysis

The statistical analysis (χ^2) of the relationship between tumor size, tumor number per kidney, histological type, and sclerosis was performed using the SPSS statistical package [12]. The number of adenomas per kidney was used to define solitary or multiple adenomas. Tumor size was defined as < or ≥0.5 cm in diameter. For the histological study we considered two types: a tubulopapillary pattern of small cells with basophilic or oncocytic cytoplasm, and a solid or tubular pattern with clear cells. For the sclerosis study we considered absent sclerosis, diffuse sclerosis, peritumoral sclerosis and diffuse sclerosis associated with peritumoral sclerosis.

Results

Autopsy Findings

Group 1. We studied 29 solitary and multiple adenomas (table 1) observed in 22 kidneys from 20 cases (4%). The distribution of the cadavers according to sex and age was 392 males and 108 females with ages ranging from 20 to 96 years old. Adenomas appeared between the 2nd and 8th decades with the highest incidence in the 6th decade. The male:female ratio was 19:1. Most of the tumors were <0.5 cm in diameter (table 2) and all of them displayed a papillary or tubulopapillary pattern with small cells containing basophilic cytoplasm. Two of them had larger cells with eosinophilic cytoplasm of the oncocytic type and small regular nuclei. In this group we observed an incidence of 39% of renal cysts. In 8 of the kidneys with adenoma there were renal cysts associated (40%). Only in 1 case was the relationship between the adenoma, papillary pattern, and the cyst evident (fig. 1). Renal stromal sclerosis was associated with tumors in 10 cases (50%; table 3).

Group 2. We studied adenomas in 29 kidneys from 29 cases (0.58%). The distribution by age of the patients with adenoma was between 1 and 84 years old and the male:female ratio was 8.3:1. The tumors, solitary or multiple (ta-

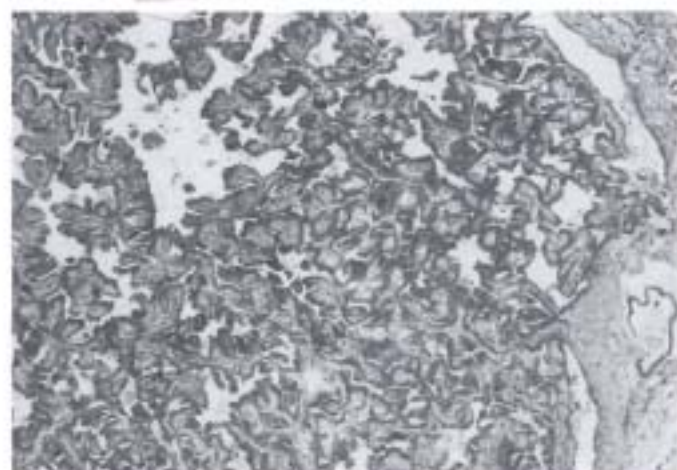


Fig. 1. Renal adenoma developing from the cystic cell lining. HE, × 125.

Table 1. Distribution of solitary and multiple adenomas

	Group 1	Group 2	Group 3	Group 4	Total
Solitary	7	22	12	1	42 (63.6%)
Multiple	13	7	4	-	24 (36.4%)

Table 2. Distribution of adenoma size

	Group 1	Group 2	Group 3	Group 4	Total
<0.5 cm	13	20	7	1	41 (62.1%)
≥0.5 cm	7	9	9	-	25 (37.9%)

Table 3. Distribution of renal stromal sclerosis associated with adenomas

	Group 1	Group 2	Group 3	Group 4	Total
Diffuse mild	4	9	5	-	18 (27.2%)
Diffuse severe	-	2	3	-	5 (7.5%)
Peritumoral	6	6	2	-	14 (21.2%)
Mixed	-	4	3	-	7 (10.6%)
Total	10	21	13	-	44 (67.3%)

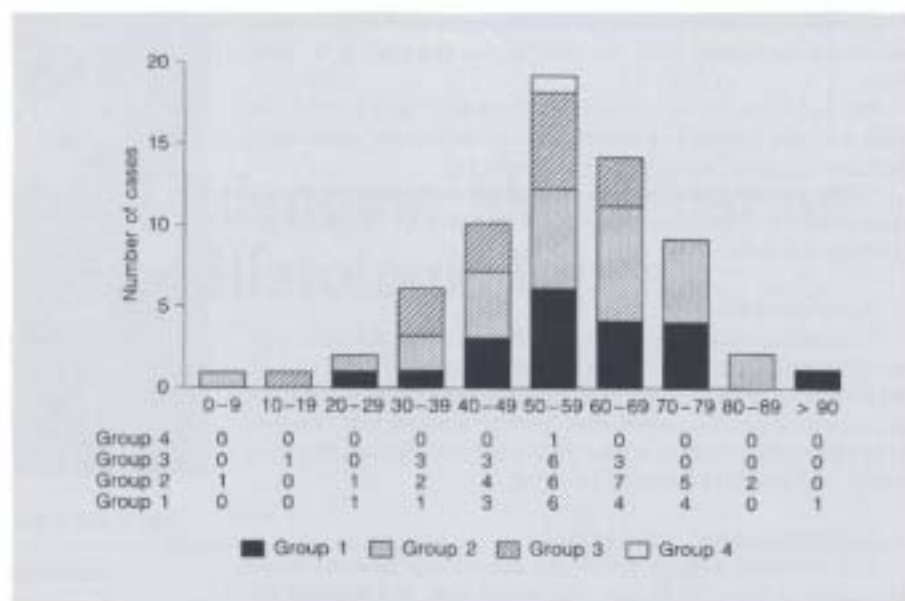


Fig. 2. Distribution of patients with renal adenoma.

ble 1) were predominantly <0.5 cm in diameter (table 2). Most of them displayed a papillary or tubulopapillary pattern, with small cells containing basophilic or eosinophilic cytoplasm. In 1 case the pattern of the tumor was solid with clear cells and, in 2 cases, the tumor pattern was tubulopapillary with clear cells. There was renal sclerosis in 21 cases (72.4%; table 3).

Nephrectomy Findings

Group 3. We studied 16 kidneys with adenoma and without carcinoma. The highest incidence of tumors was in the 6th decade with a male:female ratio of 1.3:1. The tumors, solitary and multiple (table 1), were homogeneous in distribution by size (table 2). Most displayed a papillary or tubulopapillary pattern with small cells containing basophilic cytoplasm. In 4 cases the tumors were solid with clear cells, and in 1 case, the tumor was papillary with clear cells. Renal sclerosis was associated in 13 cases (table 3).

Group 4. We found only 1 adenoma (0.5%) in a 56-year-old man and it was solitary, measuring <0.5 cm in diameter. The tumor displayed a papillary pattern, with small cells containing basophilic cytoplasm and there was no associated renal sclerosis.

Combined Findings

The combined autopsy and nephrectomy findings showed 68 kidneys in 66 cases with solitary or multiple adenoma (table 1). Adenomas were most frequently seen

Table 4. Histologic type of adenomas

	Number	%
Papillary with basophilic cells	48	80.0
Papillary with oncocytic cells	3	5.0
Papillary with clear cells	4	6.7
Solid with clear cells	5	8.3

in the 6th decade (fig. 2), with a male:female ratio of 4.9:1 and with sizes of <0.5 cm in 62.1% and ≥ 0.5 cm in 37.9% (table 2). The predominant histologic type (table 4) was the papillary pattern with small basophilic cells (fig. 3) but, in 9 cases, the pattern was solid with clear cells (fig. 4) or papillary with clear cells (fig. 5). The tumors, when multiple, present the same histologic type. Renal sclerosis of a different type was associated with adenoma in 44 cases (67.3%, table 3).

Statistical Analysis

The differences in frequency between the parameters size, number, pattern, and sclerosis, when analyzed, gave the following results.

Size, Histological Type and Number. Ninety-seven percent of adenomas of <0.5 cm in diameter exhibit a tubulopapillary pattern with basophilic or oncocytic cells, whereas 89% of larger adenomas exhibit a solid or tubulo-

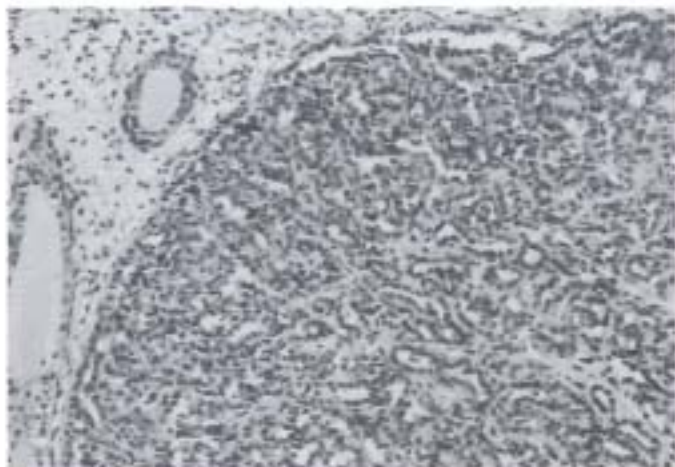


Fig. 3. Renal adenoma with a tubulopapillary pattern and basophilic cells. HE. $\times 62.5$.

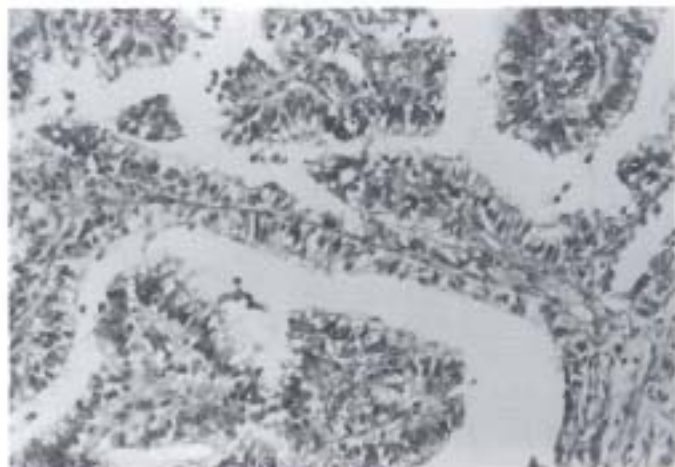

Fig. 5. Renal adenoma with a papillary pattern and clear cells. HE. $\times 125$.

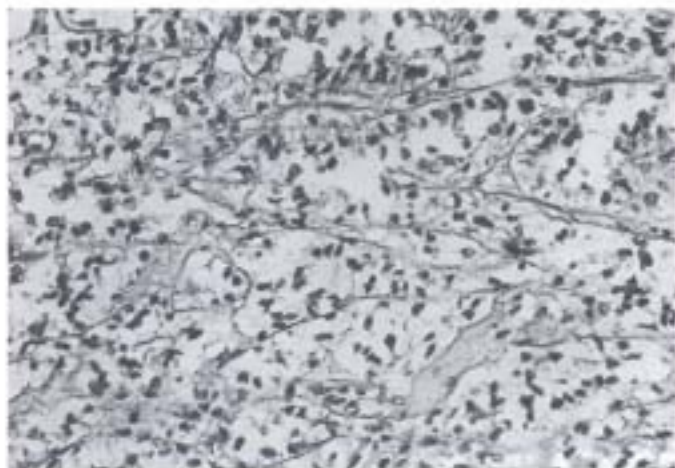


Fig. 4. Renal adenoma with a solid pattern and clear cells. HE. $\times 125$.

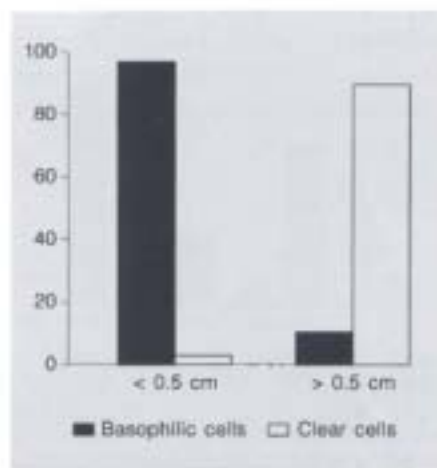


Fig. 6. Relationship between adenoma histologic type and size ($p < 0.003$).

papillary pattern with clear cells (fig. 6). These differences are highly significant ($p < 0.003$), namely when evaluating solitary adenomas ($p < 0.001$). Conversely, no statistically significant differences in histological pattern were observed for multiple adenomas ($p > 0.05$).

Sclerosis, Histological Type, Size and Number. There was a statistically significant difference ($p < 0.01$) between the grade of sclerosis and histological type of the tumors, namely between diffuse sclerosis and papillary with basophilic cells and peritumoral sclerosis and papillary or solid tumors with clear cells (fig. 7). There was also a statisti-

cally significant difference ($p < 0.009$) between sclerosis grade and tumor size (fig. 8), namely $p < 0.004$ if we do not distinguish between moderate or severe sclerosis (fig. 9). There was no statistically significant correlation ($p > 0.05$) between the sclerosis grade and the number of adenomas (fig. 10).

Considering only diffuse sclerosis without discrimination of the cases with or without peritumoral sclerosis, then the relationship between diffuse sclerosis and the tubulopapillary pattern with basophilic cells is not significant ($p > 0.05$).

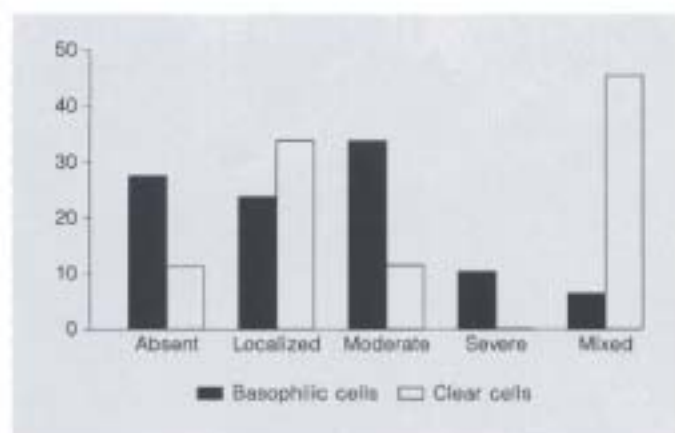


Fig. 7. Relationship between renal sclerosis grade and adenoma histologic type ($p < 0.01$).

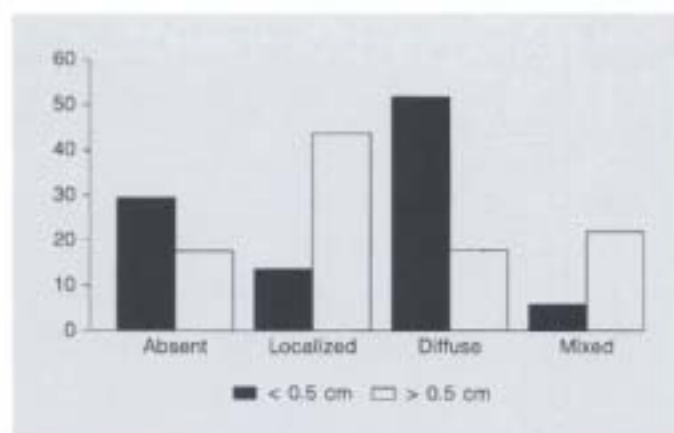


Fig. 9. Relationship between renal sclerosis grade and adenoma size ($p < 0.004$).

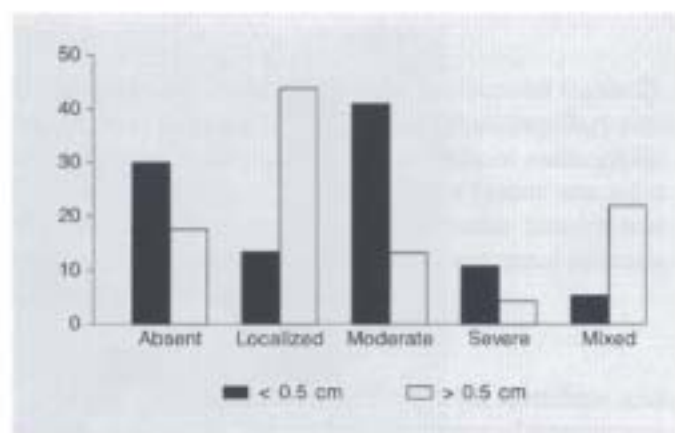


Fig. 8. Relationship between renal sclerosis grade and adenoma size ($p < 0.009$).

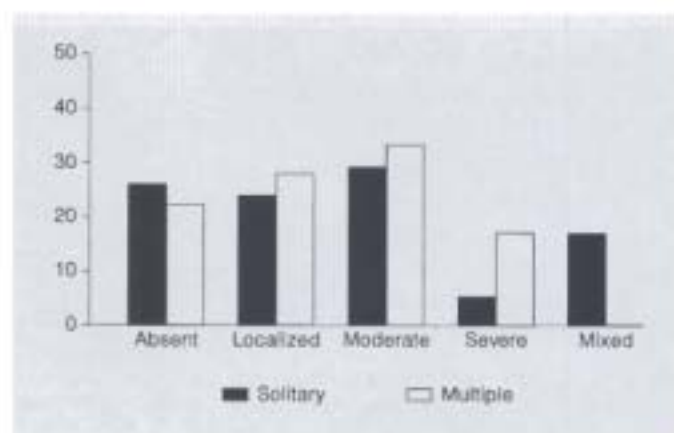


Fig. 10. Relationship between renal sclerosis grade and solitary or multiple adenomas ($p > 0.05$).

Discussion

In the present study the incidence of adenomas at autopsy is similar to that found by other authors [2, 5, 13, 14]. However, there was an important difference between the incidence of adenomas in forensic necropsies (4%) and hospital necropsies (0.56%). These differences probably result from the methodology used in the study of these 2 groups. In forensic necropsies the kidneys were sectioned serially at approximately 0.2 cm thickness, but the kidneys of hospital necropsies were variably sectioned with no intention of detecting small lesions.

The higher rate of adenomas in older patients, observed in our series, may explain the differences in the incidence of these tumors in the series of Reese and Winstanley [15] and Xipell [16], 14.6 and 22.4%, respectively, because 77 and 88.4% of the patients were more than 50 years old. In our forensic cases only 54.8% of the patients were over 50 years of age.

Cystic transformation with hyperplasia of the tubular lining cells has been considered in the pathogenesis of adenoma associated with hemodialysis or congenital cysts [18-22]. In the present study the incidence of renal cysts in the 500 unselected necropsies was 39% [11], very close

to the 40% incidence observed in the kidneys with adenoma of the same series, and only in 1 case was it possible to establish the relationship between adenoma of the papillary type and the cyst. The pathogenic relationship between sclerosis and adenoma suggested by some authors [10, 13, 15] must, in our opinion, be reevaluated. The association between localized (peritumoral) sclerosis with larger adenomas exhibiting a solid or tubulopapillary pattern with clear cells was statistically significant. The relationship between diffuse sclerosis and the smaller adenomas with a tubulopapillary pattern and basophilic cells was statistically significant only when we discriminated the cases with or without peritumoral sclerosis. There is also a large number of cases with adenoma and without renal sclerosis (fig. 9). Thus the pathogenic relationship between diffuse sclerosis and small-sized adenomas with a papillary or tubulopapillary pattern and basophilic cells is not, in our opinion, clearly defined.

Our results suggest two different histologic types of adenomas. Small adenomas are the most common type, frequently multiple, exhibiting a papillary or tubulopapillary pattern with basophilic or oncocytic cells, and usually associated with diffuse renal sclerosis. The other types of adenoma included the less frequent large adenoma, usual-

ly solitary, exhibiting a solid or tubulopapillary pattern with clear cells and also usually associated with localized (peritumoral) sclerosis that is apparently secondary to tumor development.

The low incidence of papillary carcinoma in our study of renal carcinoma [17] and the fact that in group 4 of the present study we observed only one adenoma suggest that papillary adenoma with basophilic cells is probably not a cancer precursor. Even if we consider that the number of adenomas in group 4 is very low because there was not an intentional search for these tumors, the incidence of adenomas in kidneys with carcinoma in other studies [23] is not higher than the general incidence. On the other hand, the larger adenomas with a solid or papillary pattern and clear cells, frequently solitary, may be a morphologic precursor of renal carcinoma or already a small carcinoma, as pointed out elsewhere [23]. In our study of renal carcinoma [17] we observed a small tumor of <3 cm with a solid pattern and clear cells that metastasized in the vertebral column.

In conclusion, our results support the hypothesis that adenoma must be characterized, for prognostic evaluation, not only by size but, principally, by the pattern and cellular type.

References

- Bell ET: A classification of renal tumors with observations on the frequency of the various types. *J Urol* 1938;39:238-243.
- Cristol DS, McDonald JR, Erimet JL: Renal adenomas in hypernephromatous kidneys: A study of their incidence, nature and relationship. *J Urol* 1946;55:18-27.
- Murphy GP, Mostofi FK: Histological assessment and clinical prognosis of renal adenoma. *J Urol* 1970;103:31-36.
- Fisher ER, Horvat B: Comparative ultrastructural study of so-called renal adenoma and carcinoma. *J Urol* 1972;108:382-386.
- Mercier G, Debled G: L'adénome du rein. *Acta Urol Belg* 1976;44:209-248.
- Hard GC, Butler WH: Ultrastructural aspects of renal adenocarcinoma induced in the rat by dimethylnitrosamine. *Cancer Res* 1971;31:366-372.
- Wallace AC, Naim RC: Renal tubular antigens in kidney tumors. *Cancer* 1972;29:977-981.
- Johannessen JV, Eker R, Sobrinho-Simoes M: The ultrastructure of hereditary renal adenomas and adenocarcinomas in rats. *J Submicrosc Cytol* 1980;12:463-473.
- Talamo ST, Shonard JW: Small renal adenocarcinoma with metastases. *J Urol* 1980;124:132-134.
- Budin RE, McDonnell PJ: Renal cell neoplasms. *Arch Pathol Lab Med* 1984;108:138-140.
- Reis M, Faria V, Lindoro J, Adolfo A: The small cystic and noncystic noninflammatory renal nodules. *J Urol* 1988;140:721-724.
- Statistical Package for the Social Sciences: SPSS-X User's Guide, ed 2. Chicago, SPSS, 1987.
- Masset A, Balo J: Les adénomes multiples du rein. *Bull Cancer* 1942;49:196-205.
- Sacchettoni-Logroscino G, Sentinelli S, Salgarollo G, Rosati F: Gli adenomi renali. Aspetti morfologici e prognostici. *Pathologica* 1983;75:847-860.
- Reese AJM, Winstanley DP: The small tumor-like lesions of the kidney. *Br J Cancer* 1958;12:507-516.
- Xipell JM: The incidence of benign renal nodules: A clinico-pathologic study. *J Urol* 1971;106:503-506.
- Reis M, Faria V: Renal carcinoma. Reevaluation of prognostic factors. *Cancer* 1988;61:1192-1199.
- Hughson MD, Henningar GR, McMannus JFA: Atypical cysts, acquired renal cystic disease and renal cell tumors in end stage dialysis kidney. *Lab Invest* 1980;42:475-480.
- Fayemi AO, Ali M: Acquired renal cysts and tumors superimposed on chronic primary kidney diseases. *Pathol Res Pract* 1980;168:73-83.
- Bretan PN, Busch MP, Hricak H, Williams RD: Chronic renal failure: A significant risk factor in the development of acquired renal cysts and renal cell carcinoma. *Cancer* 1986;57:1871-1879.
- Sherman ME, Silverman ML, Bakogh K, Tan SSG: Multilocular renal cysts. *Arch Pathol Lab Med* 1987;11:722-736.
- Bernstein J, Evan AP, Gardner KD: Epithelial hyperplasia in human polycystic kidney disease. *Am J Pathol* 1987;129:92-101.
- Holm-Nielsen P, Olsen TS: Ultrastructure of renal adenoma. *Ultrastruct Pathol* 1988;12:27-39.